

Reproducibility of the Implant Crown Aesthetic Index – Rating Aesthetics of Single-Implant Crowns and Adjacent Soft Tissues with Regard to Observer Dental Specialization

Peter Gehrke, Dr Med Dent;* Marco Degidi, MD, DDS;† Zitta Lulay-Saad, Dr Med Stom;‡
Günter Dhom, Prof Dr Med Dent§

ABSTRACT

Aim: The Implant Crown Aesthetic (ICA) Index evaluates the aesthetic outcome of implant-supported single crowns in the anterior zone by awarding nine points for the shape, color, and surface characteristics of the crowns and surrounding soft tissue. The aim of this study was to measure the reproducibility of the ICA Index and assess the influence exerted by the examiner's degree of dental specialization.

Materials and Methods: Ten examiners (two general dentists, two prosthodontists, two oral surgeons, two orthodontists, and two dental technicians) applied the ICA Index to 23 implant-supported single crowns twice at an interval of 4 weeks. The inter- and intra-examiner ratings were analyzed. Cohen's kappa (K) was used to measure the interexaminer reliability of estimations by two appraisers at a significance level of $p < .05$.

Results: Within the various parameters, the observer agreement ranged 53 to 81%. All the examiners achieved moderate agreement between the first and second ratings, whereby Cohen's kappa was 0.49 ($p < .001$). The most agreement was obtained by surgeons (K = 0.62, substantial) and the least by orthodontists (K = 0.24, sufficient). The lowest level of agreement with other occupational groups was manifested by the orthodontists ($\leq 44.3\%$). The ICA Index produced a moderate Cohen's kappa of 0.42 and agreement amounting to 67% between the two ratings within the occupational groups. There was minimum agreement among the occupational groups (Cohen's K = 0.11–0.37, observer agreement: 40.2–66.3%); again, the least agreement was between the orthodontists and others.

Conclusions: The ICA Index resulted in poor to moderate intra- and interexaminer agreement. The validity and reproducibility of the ICA indexing as an objective tool in rating implant aesthetics is questionable.

KEY WORDS: aesthetics, Implant Crown Aesthetic (ICA) Index, implant-supported single-tooth restoration, peri-implant soft tissue

INTRODUCTION

The aesthetic integration of an implant-supported dental restoration frequently constitutes a challenge.

*Private practice, Ludwigshafen, Germany; †private practice, Bologna, Italy; ‡private practice, Ipsheim, Germany; §professor of Management of Dental and Oral Medicine, Steinbeis-University, Berlin, Germany

Reprint requests: Peter Gehrke, Bismarckstrasse 27, 67059 Ludwigshafen, Germany; e-mail: dr-gehrke@prof-dhom.de

© 2008, Copyright the Authors
Journal Compilation © 2008, Wiley Periodicals, Inc.

DOI 10.1111/j.1708-8208.2008.00107.x

As a genuine treatment alternative, implant-supported restorations should conform to the good aesthetic outcome of conventional crown and bridge technique, or provide a better outcome. For many patients, an aesthetic result is the main motivating factor when deciding in favor of dental implantation.¹⁻³ While criteria concerning the functional assessment of implants (stability, radiographic bone loss, prosthetic complications, and peri-implant hygiene)⁴⁻⁷ are prevalently employed for the determination of implant success, the use of newer indices for objective evaluation of aesthetics must, on the other hand, be checked for validity. Measured by the abundance of implant dentistry publications, which are

chiefly concerned with osseointegration processes, clinical success rates, and many examples of top-quality restorative techniques, few studies are concerned with the aesthetic parameters of implant restorations.^{8,9} There is a lack of objective methods of measurement in order to assess aesthetic quality. In the "Consensus Statements and Recommended Clinical Procedures Regarding Esthetics in Implant Dentistry," Belser and colleagues¹⁰ called for the inclusion of aesthetic outcome in clinical studies.

Factors that have a major influence on aesthetics are summarized as follows^{8,11-15}:

Individual patient factors:

- gingival morphology and spatial orientation;
- periodontal biotype;
- smile line;
- occlusion;
- interdental and interocclusal space available.

Surgical factors:

- soft tissue management;
- bone repair;
- extent of surgery with or without flap;
- three-dimensional implant position.

Prosthetic factors:

- morphology, proportion, and color of the crown;
- shape, texture, and color of the soft tissue;
- prosthetic components and materials.

In order to evaluate and record aesthetics, a fundamental distinction may be drawn between subjective and objective methods. One subjective method is for the patient to answer questionnaires on which he or she can express his or her satisfaction and any deficiencies that may exist. However, this subjective assessment is not suitable for evaluating any potential sources of error or scope for improvement in restoration.¹⁶ Objective methods by a professional examiner based on defined criteria are rare in the field of aesthetic implant dentistry.

Meijer and colleagues¹⁷ published a new index for the assessment of the aesthetics of implant-supported single crowns in 2005. This Implant Crown Aesthetic (ICA) Index appears to be of particular interest because it takes into account not only parameters for the evaluation of the implant crown but also the peri-implant mucosa. In a pilot study to investigate the reliability of this new rating scale, evaluations of treatment outcome

were investigated on 24 implant-supported single crowns by four examiners (two oral surgeons and two prosthodontists) twice with an interval of 4 weeks. Within the limited group of dentists questioned (four), the results showed good intraobserver agreement between the first and second assessment but considerable discrepancies in the evaluation of occupational groups.¹⁷ In a current evaluation of the influence of different bone augmentation techniques and materials on the aesthetics of implant-supported restorations in the anterior maxilla, the same occupational group confirmed that the ICA Index was objective in the evaluation of implant restorations by a prosthodontist.⁹ Studies concerning the validity and reproducibility of the ICA Index have to be performed. The question of whether the assessment of the aesthetic outcome of an implant-supported restoration is subject to the subjective appraisal of the observer or whether there are objective comprehensible rules of evaluation remains to be clarified.

The aim of this study was to measure the reproducibility of the ICA Index and assess the influence exerted by the examiner's degree of dental specialization.

MATERIALS AND METHODS

Standardized intraoral photographs of 23 patients with maxillary anterior implant-supported single crowns and adjacent peri-implant soft tissue were evaluated (XiVE® implants, Dentsply Friadent, Mannheim, Germany). All images were available as A4-size black-and-white and color prints. Nine parameters influencing the aesthetic outcome were selected for questioning purposes: anatomic shape, color, and surface characteristics of the crown and peri-implant soft tissue. Two general dentists, two prosthodontists, two oral surgeons, two orthodontists, and two dental technicians evaluated the 23 implant-supported single crowns and the peri-implant mucosa by providing nine evaluation index points. The grading used the ICA suggested by Meijer and colleagues¹⁷ and was performed twice by each examiner at an interval of 4 weeks. The contralateral tooth and the adjacent soft tissue served as reference. The suggested standards of "ideal tooth shape and position" were not taken into account, because they are based on young healthy women and disregard the individual parameters of facial proportions, height, sex, characteristics of adjacent teeth, and individual

TABLE 1 Rating Parameters of the Implant Crown Aesthetic Index according to Meijer and Colleagues¹⁷

No.	Item	Parameter	Points
1	Mesiodistal dimension of the crown (crown width mesiodistally)	Highly undersized	5
		Slightly undersized	1
		No deviation	0
		Slightly oversized	1
		Highly oversized	5
2	Position of the incisal edge	Highly undersized	5
		Slightly undersized	1
		No deviation	0
		Slightly oversized	1
		Highly oversized	5
3	Labial convexity of the crown	Highly undersized	5
		Slightly undersized	1
		No deviation	0
		Slightly oversized	1
		Highly oversized	5
4	Color and translucency of the crown	Major deviation	5
		Minor deviation	1
		No deviation	0
5	Texture of the crown	Major deviation	5
		Minor deviation	1
		No deviation	0
6	Position of the vestibular margin of the peri-implant mucosa (height of the gingiva)	Deviation of >1.5 mm	5
		Deviation of <1.5 mm	1
		No deviation	0
7	Position of the mucosa in the proximal spaces (interdental papilla)	Deviation of >1.5 mm	5
		Deviation of <1.5 mm	1
		No deviation	0
8	Contour of the vestibular structure of the mucosa	Highly undersized	5
		Slightly undersized	1
		No deviation	0
		Slightly oversized	1
		Highly oversized	5
9	Color and surface of the existing attached gingiva (keratinized gingiva)	Major deviation	5
		Minor deviation	1
		No deviation	0

harmony.¹⁵ The various categories that were applied for the assessment of each parameter within the ICA Index are listed in Table 1. One point was awarded for any slight deviation and 5 points for any major deviation. The ICA Index was then calculated as follows: 0 points = excellent; 1 point = satisfactory; 2 to 4 points = moderate; and 5 points or more = poor. A major deviation in a single criterion would result in a poor aesthetic assessment.¹⁷

Statistical Analysis

The statistical analyses were performed using software packages SPSS® 11.5 (SPSS Inc., 2005, Chicago, IL, USA) and SAS Version 8 (SAS Heidelberg, Heidelberg, Germany). The assessments of 23 images by the 10 examiners applying nine evaluation criteria took place at 2 points in time. Consequently, the data comprised 10 × 23 × 9 × 2 = 4, 140 individual evaluations. However, in

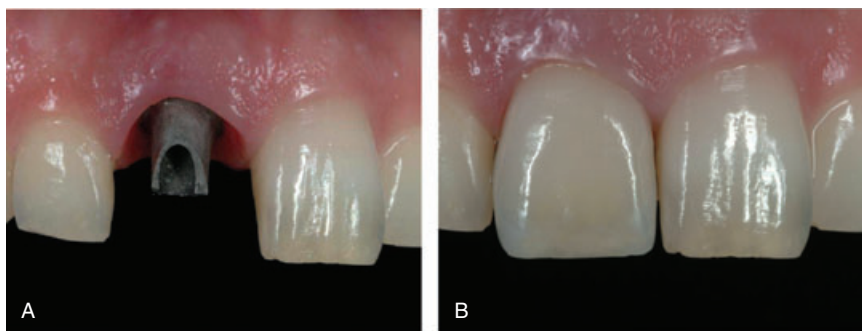


Figure 1 A and B, Implant-supported single-tooth restoration. Slight deviation in the labial surface characteristics of the crown and the color of the peri-implant mucosa. The total score is 2 points, which indicates satisfactory aesthetics.

isolated cases, there were missing values because of a lack of assessments for individual criteria. The following statistical tests were used.

Cohen's Kappa. Cohen's kappa is a statistical measure of the interexaminer reliability of estimations by two appraisers.¹⁸

The equation for Cohen's kappa (K) is:

$$K = (p_0 - p_c) / (1 - p_c)$$

where p_0 is the measured agreement between the two examiners, and p_c is the expected chance agreement. This measure is the agreement that is beyond any expected chance agreement. If the examiners agree on all assessments, $K = 1$. If only chance agreements are measured, the value $K = 0$.

K can be rated as follows¹⁸:

<0.2: "poor"

0.21 to 0.40: "fair"

0.41 to 0.60: "moderate"

>0.60: "substantial"

Observer Agreement. This test determines the simple agreement rates as a percentage with the 95% confidence intervals.¹⁸

The significance level of both tests was at $p < .05$.

Case Studies

Figures 1–3 demonstrate, by way of example, the application of the ICA Index for evaluating the overall aesthetic outcome.

RESULTS

Agreement of First and Second Ratings

There was considerable agreement between the individual scores of the first and second ratings (Figure 4). This particularly applies to the scores given not only for the peri-implant mucosa (items 6–9) but also the mesiodistal dimension of the crown and the position of

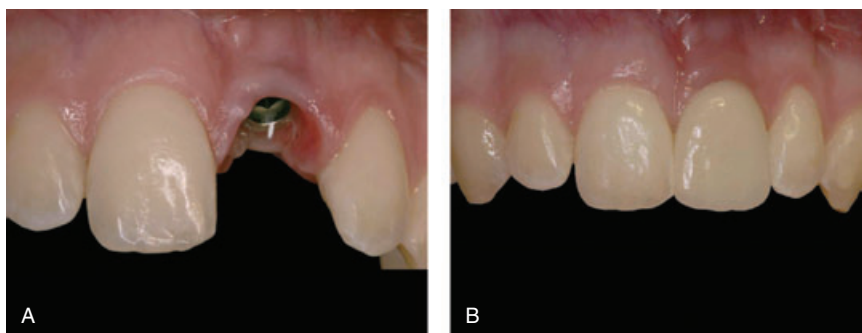

Figure 2 A and B, Implant-supported single-tooth restoration. The mesiodistal dimension of the crown is slightly overcontoured, and there is a slight deviation in the contour, color, and surface of the labial mucosa. The total score is 4, which indicates moderate aesthetics.

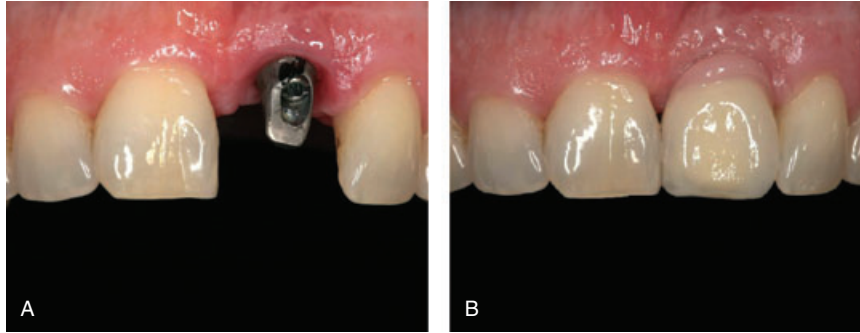


Figure 3 A and B, Implant-supported single-tooth restoration. The mesiodistal dimension of the crown is slightly overcontoured, and there is a slight mismatch in color and translucency of the crown, a gross mismatch in the position of the labial mucosal margin, and a gross deviation in the position of mucosa in the proximal embrasures and the colour and surface of the labial mucosa. The total score is 8, which indicates poor aesthetics.

the incisal edge (items 1 and 2). The deviations for items 3 to 5 appeared to be larger. Despite the apparently good agreement between the mean values, the high standard deviations point to an occasionally substantial variation within the individual questions (Table 2). Very good ratings below 1 point were given relatively often for the outcomes of the mesiodistal dimension, labial convexity, and position of the incisal edge (items 1–3), while the outcomes for the anatomic shape, color, and texture of the peri-implant mucosa (items 6–9) obtained a lower score. Even though the mean values of the ICA scores for the various parameters exhibited considerable agreement, when observer agreement was applied, it was evident that the agreements only varied between 53 and 81% (Table 3). The largest agreements were 81 and 77% for ICA items 6

and 7. The assessments of ICA items 1 and 3 showed less agreement at 53 and 58%, respectively.

Intraobserver Agreement/Cohen's Kappa

In a classification of the examiners according to various occupational groups, there was a high level of agreement within the groups between the first and second rating (Figure 5). It became evident that on the average, the dental technicians had given a higher score (equivalent to a poorer ICA rating) and the orthodontists had awarded a lower score (equivalent to a better evaluation) (Figure 6). All the examiners achieved moderate agreement between the first and second ratings according to Landis and Koch,¹⁸ whereby Cohen's kappa was 0.49 ($p < .001$) (Tables 4–7). The most agreement was obtained by surgeons ($K = 0.62$, substantial) and the

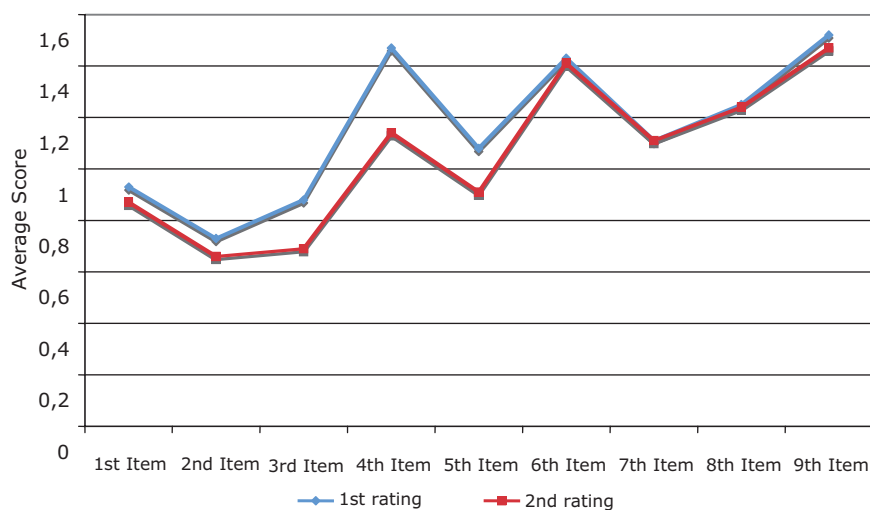


Figure 4 Average score per item in the first and second ratings.

TABLE 2 Score Per Item in the First and Second Ratings (Mean Value ± SD)

Item	First Rating	Second Rating
1	0.93 ± 1.41	0.87 ± 1.30
2	0.73 ± 1.08	0.66 ± 1.05
3	0.88 ± 1.36	0.69 ± 1.12
4	1.47 ± 1.89	1.14 ± 1.63
5	1.08 ± 1.63	1.14 ± 1.63
6	1.43 ± 1.90	1.41 ± 1.42
7	1.11 ± 1.74	1.11 ± 1.74
8	1.25 ± 1.76	1.24 ± 1.71
9	1.52 ± 1.87	1.47 ± 1.75

least by orthodontists (K = 0.24, sufficient). The ICA Index produced a moderate Cohen’s kappa of 0.42 and an agreement amounting to 67% between the two ratings within the occupational groups (Tables 8 and 9).

Interobserver Agreement/Cohen’s Kappa

A direct comparison among the occupational groups demonstrated a minimum agreement (Cohen’s K = 0.11–0.37, observer agreement: 40.2–66.3%). This level of agreement can be interpreted as “minimal” to “sufficient” according to Landis and Koch.¹⁸ The least

TABLE 3 Observer Agreement between the First and Second Ratings in Relation to the Various Items of the Implant Crown Aesthetic Index

Item	n	Observer Agreement (%)	Higher Figures in the Second Rating (%)	Higher Figures in the First Rating (%)
1	229	53	21	26
2	229	60	19	21
3	229	58	21	21
4	227	62	25	14
5	226	56	24	19
6	223	81	9	10
7	227	77	11	12
8	229	67	17	16
9	229	69	15	17

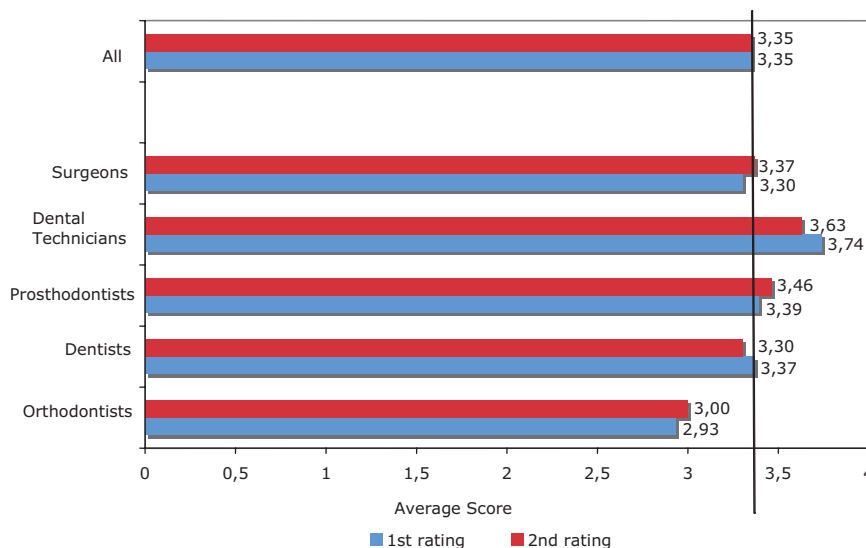


Figure 5 Average score in the first and second ratings by occupational group (the vertical line is the mean value of all the occupational groups).

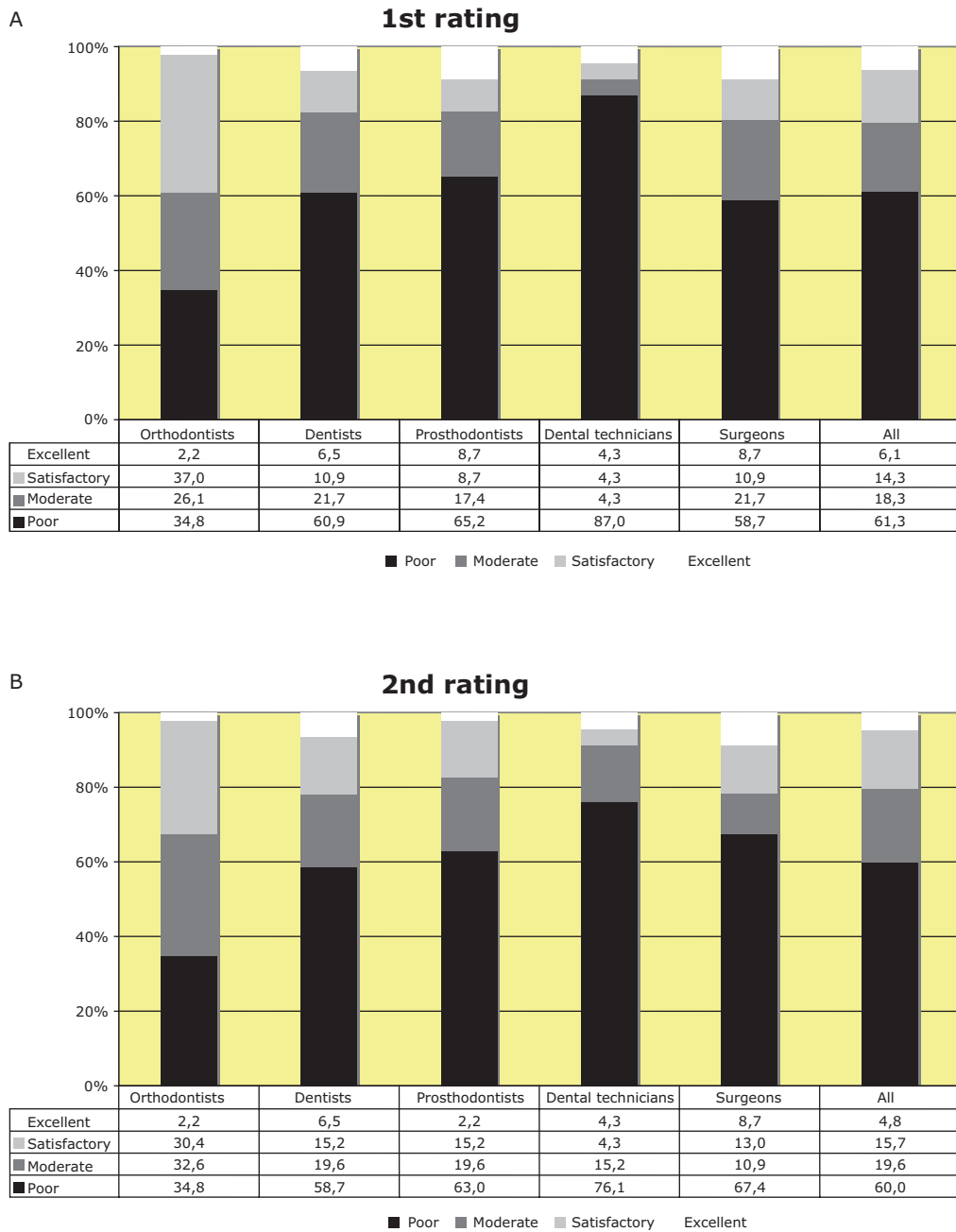


Figure 6 A and B, Implant Crown Aesthetic Index in various rater groups in the first and second ratings.

agreement was again between orthodontists and others (Tables 10 and 11).

DISCUSSION

With increasing surgical reliability of implant dentistry and documented high success rates,¹⁹⁻²¹ the standards expected of implant-supported dental restorations are rising. Especially on the part of patients, there is a growing desire for an aesthetic solution^{3,22} equivalent to

the appearance of natural teeth. Current data concerning the long-term results of dental implants demonstrate that the success of the individual treatment is still being measured by the survival of the implant or superstructure.^{19,23} Although within the context of a rise in aesthetic awareness and the resulting standards expected by patients and dental professionals, there is still a lack of comparative clinical studies on the long-term aesthetic outcome of implant-supported restorations. Thirty years ago, the California Dental Association introduced

TABLE 4 Agreement between the First and Second Ratings (Cohen's Kappa)				
	K	95% CI	<i>p</i>	Evaluation of Agreement (75)
Orthodontists	0.24	0.15–0.31	<i>p</i> < .001	Sufficient
Dentists	0.54	0.47–0.60	<i>p</i> < .001	Moderate
Prosthodontists	0.46	0.39–0.53	<i>p</i> < .001	Moderate
Dental technicians	0.51	0.46–0.56	<i>p</i> < .001	Moderate
Surgeons	0.62	0.57–0.68	<i>p</i> < .001	Substantial
All raters	0.49	0.46–0.52	<i>p</i> < .001	Moderate

CI = confidence interval.

an objective rating system for conventional crown and bridge prostheses, although admittedly, it cannot be applied to implant-supported dental restorations. First, the main focus of this rating system only considers functional aspects, although it also covers aesthetic components such as color, translucency, contouring, and

harmonious integration of the dental restoration into the environment. Second, it incorporates factors that are of no relevance to implant-supported reconstructions, for example, the development of secondary caries.^{24,25} In the relevant guidelines concerning dental implants, only functional parameters are used as assessment criteria.²⁶

TABLE 5 Agreement between the First and Second Ratings (Observer Agreement)				
	%	95% CI	<i>n</i>	Levels of Agreement (<i>n</i>)
Orthodontists	53.8	48.8–56.7	409	220
Dentists	69.1	64.4–73.4	414	286
Prosthodontists	62.7	57.8–67.4	405	254
Dental technicians	64.6	59.8–69.3	410	265
Surgeons	73.2	68.7–77.5	411	301
All raters	64.3	62.6–66.8	2,049	1,326

CI = confidence interval.

TABLE 6 Agreement between the Occupational Groups (Cohen's Kappa)				
	K	95% CI	<i>p</i>	Evaluation of Agreement (75)
Orthodontists vs dentists	0.21	0.16–0.26	<i>p</i> < .001	Sufficient
Orthodontists vs prosthodontists	0.17	0.11–0.21	<i>p</i> < .001	Minimal
Orthodontists vs dental technicians	0.06	0.01–0.11	<i>p</i> = .002	Minimal
Orthodontists vs surgeons	0.17	0.12–0.24	<i>p</i> < .001	Minimal
Dentists vs prosthodontists	0.34	0.28–0.39	<i>p</i> < .001	Sufficient
Dentists vs dental technicians	0.33	0.28–0.38	<i>p</i> < .001	Sufficient
Dentists vs surgeons	0.46	0.41–0.50	<i>p</i> < .001	Moderate
Prosthodontists vs dental technicians	0.27	0.23–0.32	<i>p</i> < .001	Sufficient
Prosthodontists vs surgeons	0.35	0.29–0.39	<i>p</i> < .001	Sufficient
Dental technicians vs surgeons	0.28	0.22–0.33	<i>p</i> < .001	Sufficient

CI = confidence interval.

TABLE 7 Agreement between the Occupational Groups (Observer Agreement)

	%	95% CI	<i>n</i>	Levels of Agreement (<i>n</i>)
Orthodontists vs dentists	48.7	45.3–52.2	823	401
Orthodontists vs prosthodontists	44.3	40.9–47.8	814	361
Orthodontists vs dental technicians	34.9	31.7–38.3	819	286
Orthodontists vs surgeons	45.0	41.6–48.5	820	369
Dentists vs prosthodontists	54.6	51.1–58.0	819	447
Dentists vs dental technicians	52.9	49.4–56.4	824	436
Dentists vs surgeons	62.5	59.1–65.9	825	516
Prosthodontists vs dental technicians	48.0	44.5–51.5	815	391
Prosthodontists vs surgeons	54.5	51.1–58.0	816	445
Dental technicians vs surgeons	48.6	45.1–52.1	821	399

CI = confidence interval.

One system of aesthetic assessment that is common in dentistry are the so-called Ryge criteria, which were developed by Ryge²⁷ in 1973 and by McComb²⁸ and Pelka and colleagues²⁹ in the form of the US Health Service Criteria. Here, numerous aesthetic visual param-

eters are obtained by two independent examiners, including anatomic shape and surface structure of the reconstruction, color adaptation, and the course of the soft-tissue transition zone. However, the Ryge criteria were chiefly developed for the assessment of composite

TABLE 8 Implant Crown Aesthetic Index: Agreement between the First and Second Ratings (Cohen's Kappa)

	K	95% CI	<i>p</i>	Evaluation of Agreement (75)
Orthodontists	0.07	0.00–0.26	<i>p</i> = .455	Minimal
Dentists	0.40	0.21–0.60	<i>p</i> < .001	Sufficient
Prosthodontists	0.27	0.11–0.44	<i>p</i> = .005	Sufficient
Dental technicians	0.54	0.23–0.78	<i>p</i> < .001	Moderate
Surgeons	0.77	0.62–0.93	<i>p</i> < .001	Substantial
All raters	0.42	0.33–0.53	<i>p</i> < .001	Moderate

CI = confidence interval.

TABLE 9 Implant Crown Aesthetic Index: Agreement between the First and Second Ratings (Observer Agreement)

	%	95% CI	<i>n</i>	Levels of Agreement (<i>n</i>)
Orthodontists	37.0	23.2–52.5	46	17
Dentists	65.2	49.8–78.7	46	30
Prosthodontists	60.9	45.4–74.9	46	28
Dental technicians	84.8	71.1–93.7	46	39
Surgeons	87.0	73.7–95.1	46	40
All raters	67.0	60.5–73.0	230	154

CI = confidence interval.

TABLE 10 Implant Crown Aesthetic Index: Agreement between the Occupational Groups (Cohen's Kappa)

	K	95% CI	<i>p</i>	Evaluation of Agreement (75)
Orthodontists vs dentists	0.24	0.08–0.38	<i>p</i> < .001	Sufficient
Orthodontists vs prosthodontists	0.15	0.04–0.25	<i>p</i> = .011	Minimal
Orthodontists vs dental technicians	0.11	0.02–0.22	<i>p</i> = .017	Minimal
Orthodontists vs surgeons	0.17	0.07–0.30	<i>p</i> = .005	Minimal
Dentists vs prosthodontists	0.26	0.13–0.41	<i>p</i> < .001	Sufficient
Dentists vs dental technicians	0.15	0.02–0.30	<i>p</i> = .021	Minimal
Dentists vs surgeons	0.37	0.24–0.50	<i>p</i> < .001	Sufficient
Prosthodontists vs dental technicians	0.25	0.12–0.38	<i>p</i> < .001	Sufficient
Prosthodontists vs surgeons	0.20	0.09–0.33	<i>p</i> = .003	Minimal
Dental technicians vs surgeons	0.20	0.05–0.34	<i>p</i> = .002	Minimal

CI = confidence interval.

restorations, so here too, many items do not apply to implant-supported dental restorations.

Chang and colleagues¹ interviewed orthodontists and patients to evaluate the aesthetic outcome of implant-supported single-tooth restorations using standardized questionnaires. Seven variables were obtained from the patients and assessed according to visual analogue scales. The results confirm a high level of patient satisfaction with the outcome of treatment. It is evident that with the exception of the issue of abutment visibility, the appearance achieved was rated as being good to very good for all parameters. The picture was contradictory in the assessment of these patient cases by prosthodontists who had received a dental questionnaire. It

became apparent that the prosthodontists questioned gave the treatment outcome a much lower rating than the patients. In addition, there was a much greater range of variation within the assessments of individual criteria, as is demonstrated by the high standard deviations. Chang and colleagues interpreted this result to the effect that the clinicians are either more critical or they apply different standards when assessing aesthetic outcome from those applied by the patients involved themselves. In actual fact, a statistical analysis indicated that parameters such as crown shape, contact point position, color, and topography of the surrounding soft tissue had a significant influence on the rating of general satisfaction with appearance, while it was not possible to detect any

TABLE 11 Implant Crown Aesthetic Index: Agreement between the Occupational Groups (Observer Agreement)

	%	95% CI	<i>n</i>	Levels of Agreement (<i>n</i>)
Orthodontists vs dentists	47.8	37.3–58.5	92	44
Orthodontists vs prosthodontists	42.4	32.2–53.1	92	39
Orthodontists vs dental technicians	40.2	30.1–51.0	92	37
Orthodontists vs surgeons	42.4	32.2–53.1	92	39
Dentists vs prosthodontists	58.7	48.0–68.9	92	54
Dentists vs dental technicians	58.7	48.0–68.9	92	54
Dentists vs surgeons	64.1	53.5–73.9	92	59
Prosthodontists vs dental technicians	66.3	55.7–75.8	92	61
Prosthodontists vs surgeons	56.5	45.8–66.8	92	52
Dental technicians vs surgeons	63.0	52.3–72.9	92	58

CI = confidence interval.

similar connections within patient questioning.² Comparable differences from aesthetic rating on the part of patients and clinicians have also been described in other studies.^{9,30} The majority shows that the soft tissue between an implant-supported single-tooth reconstruction and the adjacent teeth has a substantial influence on the aesthetic outcome. In 1999, Jemt^{31,32} introduced a score to be able to assess the papillary volume and the height of interproximal mucosa. However, this rating is restricted to the criteria indicated and disregards the peri-implant tissue and the appearance of the dental restoration.

The range of subjective opinions on the part of the observer when evaluating aesthetics is known. In this connection, Engel and colleagues³⁰ discussed the influence of the individual notion of aesthetics in relation to the examiner's degree of specialization and called for standardization criteria for evaluating the aesthetics of single-tooth restorations. The rating criteria they proposed were axial inclination, the width of crowns at the transition point, the vertical position of the transition point, and the length of the crowns at the incisal edge. Using 40 slides of single-tooth restorations, they measured the mentioned criteria at the implant crown and at the natural reference tooth and endeavoured to create threshold values with the aid of receiver operating characteristic curves. The results indicated that with a deviation of crown length by 0.7 mm and a 1.5-mm deviation in vertical position at the transition point and a 3.5° deviation in axial inclination, the aesthetic impression when viewing an implant-restoration tooth for an upper central incisor is impaired by comparison with its natural counterpart.³⁰

In 2005, two other rating scales in addition to the ICA by Meijer and colleagues were presented for assessing the aesthetics of implant-supported single-tooth restorations. These indices aim to allow objective appraisal of the aesthetic short-term and long-term results of various surgical and prosthetic implant records. Testori and colleagues³³ published a case study on a patient with immediate implantation and immediate loading in the incisor zone and in this context proposed an index for evaluating the aesthetic outcome. The latter covers five parameters concerning the presence and stability of the mesiodistal papilla, buccopalatal alveolar ridge stability, the structure and color of peri-implant soft tissue, and gingival contour. There are up to 9 points, and that score reflects a perfect outcome. A score of 4 to 8 points is an

acceptable result, while 0 to 3 points indicates a poor aesthetic outcome.³³ Fürhauser and colleagues³⁴ presented a rating matrix for evaluating soft tissue around single-implant restorations. This Pink Esthetic Score (PES) covers seven criteria. However, the assessment of the implant crown, to replace a missing tooth, is not taken into consideration. With the exception of papilla formation the evaluation is performed by visually comparing reference teeth, that is, with the contralateral tooth in the incisor zone and adjacent tooth in the premolar zone. For the mesial and distal papilla, the categories are complete, incomplete, and absent. For each criterion, it is possible to award a score between 2 points for a very good outcome and no points for a poor outcome. The maximum score which can be achieved, 14 points, indicates an outcome that reflects complete conformity between the soft tissue of the tooth being assessed and that of the reference tooth. The PES is thus designed to allow reproducible evaluation of soft tissue around single-tooth implants.³⁴ The ICA Index from Meijer and colleagues appears to be of particular interest for assessing implant-supported single-tooth restorations, because it takes into account not only the anatomic shape, color, and surface of the crown but also the peri-implant mucosa. In the relevant literature, these parameters are regarded by the majority as differentiating between a successful aesthetic outcome and an unsuccessful one.^{8,11-15}

The reliability of the ICA was reviewed by Meijer and colleagues¹⁷ within the context of a pilot study and by Meijndert and colleagues⁹ in a prospective, randomized clinical study concerning the influence of various methods of bone augmentation on aesthetic implant outcome. According to the results of those studies, the ICA Index is regarded by the authors as an objective measuring tool for evaluating the aesthetics of implant-supported single crowns and the surrounding soft tissue. Within the context of the present study, it was deemed an attractive proposition to include a relatively large number of examiners from other dental occupational groups. Another aim was to analyze the reproducibility of the ICA comprehensively. The extension of raters to include dentists, orthodontists, and dental technicians appeared to be expedient because in modern implant dentistry, multidisciplinary teamwork is necessary in order to ensure an optimum outcome,²² and there was the general issue as to whether the examiner's level of specialization had an influence when evaluating

the aesthetics of implant-supported restorations. Even though the mean values of the ICA scores for the various parameters exhibited considerable agreement in the present study, when observer agreement was applied, it was evident that the agreements only varied between 53 and 81%. All examiners achieved only moderate agreement between the first and second ratings and a minimum interobserver agreement. Considerable discrepancies among the various occupational groups could be demonstrated. There was no congruence between the results of the studies conducted by Meijer and colleagues¹⁷ and Meijndert and colleagues⁹ and our own results.

Meijer and colleagues¹⁷ gave the reason for the discrepancy they established between the assessment of oral surgeons and prosthodontists with the aid of the ICA Index by stating that prosthodontists are confronted with prosthetic restorations and the evaluation of treatment outcome on a daily basis, so their appraisals tend to be more consistent. This hypothesis cannot be corroborated by our own results. The discrepancies found between the various occupational groups are probably not only dependent on the examiner's degree of specialization but also on individual viewpoints. This is backed up by the fact that in the present study, the assessments by orthodontists where $K = 0.24$ showed least agreement, whereby especially in that occupational group, the constant tackling of aesthetic problems should be a matter of routine because they deal with position anomalies in the anterior zone. Fürhauser and colleagues³⁴ demonstrated that orthodontists in particular were highly critical when assessing implant aesthetics, which indicates nothing with regard to the reproducibility of results within that occupational group.

In connection with the results obtained by Meijer and colleagues,¹⁷ our findings provide no indications of any occupational group-specific rating of aesthetic outcome in the case of implant-supported single crowns. In particular, the authors' call for assessment by prosthodontists, because they are allegedly most reliable, cannot be supported. Clarity on this issue could be provided by further studies encompassing larger numbers of examiners from every dental occupational group, which would appear desirable on account of the contradictions found in relation to the studies by Meijer and colleagues¹⁷ and Meijndert and colleagues.⁹ Irrespective of the reproducibility and occupational group-specific

discrepancies, there is still the issue of whether the ICA Index is objectively capable of differentiating between successful and unsuccessful restorations. Even a contradiction with regard to objective assessment, inclusion of patient satisfaction may be useful in order to provide better comparability of treatment outcomes.⁹ Using the ICA does not allow sufficiently objective assessment of implant-supported single-tooth restorations. Deficiencies arise particularly with regard to the validity and reproducibility of results.

CONCLUSIONS

In the present study, the use of the ICA Index for evaluating the aesthetics of implant-supported single-tooth restorations and peri-implant mucosa resulted in poor to moderate intra- and interexaminer agreement. The validity and reproducibility of ICA indexing as an objective tool in rating implant aesthetics is questionable.

REFERENCES

1. Chang M, Odman PA, Wennstrom JL, Andersson B. Esthetic outcome of implant-supported single-tooth replacements assessed by the patient and by prosthodontists. *Int J Prosthodont* 1999; 12:335–341.
2. Chang M, Wennstrom JL, Odman P, Andersson B. Implant supported single-tooth replacements compared to contralateral natural teeth. Crown and soft tissue dimensions. *Clin Oral Implants Res* 1999; 10:185–194.
3. Sammartino G, Marenzi G, di Lauro AE, Paolantoni G. Aesthetics in oral implantology; biological, clinical, surgical, and prosthetic aspects. *Implant Dent* 2007; 16:54–65.
4. Albrektsson T, Zarb G, Worthington P, Eriksson AR. The long-term efficacy of currently used dental implants: a review and proposed criteria of success. *Int J Oral Maxillofac Implants* 1986; 1:11–25.
5. Albrektsson T, Zarb GA. Determinants of correct clinical reporting. *Int J Prosthodont* 1998; 11:517–521.
6. Esposito M, Hirsch JM, Lekholm U, Thomsen P. Biological factors contributing to failures of osseointegrated implants. I. Success criteria and epidemiology. *Eur J Oral Sci* 1998; 106:527–551.
7. Roos J, Sennerby L, Lekholm U, Jemt T, Gröndahl K, Albrektsson T. A qualitative and quantitative method for evaluating implant success: a 5-year retrospective analysis of the Brånemark implant. *Int J Oral Maxillofac Implants* 1997; 12:504–514.
8. Belser UC, Buser D, Hess D, Schmid B, Bernard JP, Lang NP. Aesthetic implant restorations in partially edentulous patients – a critical appraisal. *Periodontol* 2000 1998; 17:132–150.

9. Meijndert L, Meijer HJA, Stellingsma K, Stegenga B, Raghoebar GM. Evaluation of aesthetics of implant-supported single-tooth replacements using different bone augmentation procedures: a prospective randomized clinical study. *Clin Oral Implants Res* 2007; 18:715–719.
10. Belser U, Buser D, Higginbottom F. Consensus statements and recommended clinical procedures regarding esthetics in implant dentistry. *Int J Oral Maxillofac Impl* 2004; 19(Suppl):73–74.
11. Chiche G. Practical crown and bridge for predictable aesthetics. *J Ir Dent Assoc* 2004; 50:118–120.
12. El Askary AES. Esthetic considerations in anterior single-tooth replacement. *Implant Dent* 1999; 8:61–67.
13. Garber DA. The esthetic dental implant: letting restoration be the guide. *J Oral Impl* 1996; 22:45–50.
14. Kois JC. Altering gingival levels: the restorative connection. I. Biologic variables. *J Esthet Dent* 1994; 6:3–9.
15. Touati B, Miara P, Nathanso D. Shape and position of teeth. In: Touati B, Miara P, Nathanson D, eds. *Esthetic dentistry and ceramic restorations*. London: Martin Dunitz, 1999: 139–160.
16. Streiner DL, Norman GR. Devising the items and scaling responses. In: Streiner DL, Norman GR, eds. *Health measurement scales: a practical guide to their development and use*. Oxford: Oxford University Press, 1995:15–53.
17. Meijer HJ, Stellingsma K, Meijndert L, Raghoebar GM. A new index for rating aesthetics of implant-supported single crowns and adjacent soft tissues – the Implant Crown Aesthetic Index. *Clin Oral Implants Res* 2005; 16:645–649.
18. Landis JR, Koch GG. The measurement of observer agreement for categorical data. *Biometrics* 1977; 33:159–174.
19. Creugers NH, Kreulen CM, Snoek PA, de Kanter RJ. A systematic review of single-tooth restorations supported by implants. *J Dent* 2000; 28:209–217.
20. De Boever AL, Keersmaekers K, Vanmaele G, Kerschbaum T, Theuniers G, De Boever JA. Prosthetic complications in fixed endosseous implant-borne reconstructions after an observation period of at least 40 months. *J Oral Rehabil* 2006; 33:833–839.
21. Pjetursson BE, Tan K, Lang NP, Bragger U, Egger M, Zwahlen M. A systematic review of the survival and complication rates of fixed partial dentures (FPDs) after an observation period of at least 5 years. *Clin Oral Implants Res* 2004; 15:625–642, 667–676.
22. Feng X, Oba T, Oba Y, Moriyama K. An interdisciplinary approach for improved functional and esthetic results in a periodontally compromised adult patient. *Angle Orthod* 2005; 75:1061–1070.
23. Scheller H, Urgell JP, Kultje C, et al. A 5-year multicenter study on implant-supported single crown restorations. *Int J Oral Maxillofac Implants* 1998; 13:212–218.
24. CDA. Quality evaluation for dental care. Guidelines for the assessment of clinical quality and professional performance. Los Angeles, CA: Dental Association, 1977.
25. CDA. Fixed prosthodontic veneers, crowns and fixed bridges. General guidelines. 2004. http://www.cda.org/library/cda_member/policy/quality/fixed-prosthetics_veneers_crowns-bridges.pdf (Accessed January 7, 2007).
26. CDA. Dental implants. General guidelines. 2004. http://www.cda.org/library/cda_member/policy/quality/dental_implants.pdf (Accessed January 7, 2007).
27. Ryge G, Snyder M. Evaluation of the clinical quality of restorations. *J Am Dent Assoc* 1973; 87:369–377.
28. McComb D. Evaluation of clinical wear of posterior composite resins. In: Van Herle G, Smith DC, eds. *Posterior composite resin dental restorative materials*. Amsterdam: Szulc, 1985:511–517.
29. Pelka M, Dettenhofer G, Reinelt C, Krämer N, Petschelt A. Validität und Reliabilität klinischer Kriterien für adhäsive Inlaysysteme. *Dtsch Zahnärztl Z* 1994; 49:921–925.
30. Engel E, Gomez RG, Axmann KD. Ästhetikbewertung von implantologischen Einzelzahnersatz. *Z Zahnärztl Implantol* 2001; 17:148–153.
31. Jemt T. Regeneration of gingival papillae after single-implant treatment. *Int J Periodontics Restorative Dent* 1997; 17:326–333.
32. Jemt T. Restoring the gingival contour by means of provisional resin crowns after single-implant treatment. *Int J Periodontics Restorative Dent* 1999; 19:20–29.
33. Testori T, Bianchi F, Del Fabbro M, et al. Implant aesthetic score for evaluating the outcome: immediate loading in the aesthetic zone. *Pract Proced Aesthet Dent* 2005; 17:123–130.
34. Fürhauser R, Florescu D, Benesch T, Haas R, Mailath G, Watzek G. Evaluation of soft tissue around single-tooth implant crowns: the pink esthetic score. *Clin Oral Implants Res* 2005; 16:639–644.